

# Caso Clínico

## Clinical Case

Sandra Saleiro<sup>1</sup>  
Adriana Magalhães<sup>2</sup>  
Conceição Souto Moura<sup>3</sup>  
Venceslau Hespanhol<sup>4</sup>

### Linfangioma cístico do mediastino

#### *Mediastinal cystic lymphangioma*

Recebido para publicação/received for publication: 06.06.06

Aceite para publicação/accepted for publication: 06.07.21

#### Resumo

O linfangioma mediastínico é uma neoplasia vascular rara, correspondendo a 0,7 a 4,5% de todos os tumores do mediastino. É um tumor benigno, que ocorre geralmente como uma massa mediastínica de crescimento lento. A maioria dos doentes está assintomática, sendo diagnosticado incidentalmente, após a realização de uma radiografia torácica de rotina. O tratamento de eleição consiste na ressecção cirúrgica completa. O prognóstico depende do grau de ressecabilidade e, se a lesão for totalmente removida, não se esperam recidivas.

Rev Port Pneumol 2006; XII (6): 731-735

**Palavras-chave:** Tumor mediastínico, linfangioma, cistomediastínico.

#### Abstract

Mediastinal lymphangioma is a rare vascular neoplasm, accounting for 0.7 to 4.5% of all the mediastinum tumors. It is a benign tumor, generally occurring as a mediastinal mass of slow growth. Most patients are asymptomatic, being incidentally diagnosed after a routine chest radiograph. The best treatment consists of complete surgical resection. Prognosis depends on the degree of resectability degree, and recurrence is not expected if the lesion is totally removed.

Rev Port Pneumol 2006; XII (6): 731-735

**Key-words:** Mediastinal tumor, lymphangioma, mediastinal cyst.

<sup>1</sup> Interna Complementar de Pneumologia

<sup>2</sup> Assistente Hospitalar Graduada de Pneumologia

<sup>3</sup> Assistente Hospitalar de Anatomia Patológica

<sup>4</sup> Chefe de Serviço de Pneumologia e Professor Auxiliar com Agregação da Faculdade de Medicina da Universidade do Porto

Hospital de São João, Porto

Serviço de Pneumologia. Director de Serviço: Professor Doutor José Agostinho Marques

Serviço de Anatomia Patológica. Directora de Serviço: Professora Doutora Fátima Carneiro

Hospital de São João

Alameda Prof. Hernâni Monteiro

4200-451 Porto

Telefone: 225512215

e-mail: sandrasaleiro@portugalmail.pt

### Introduction

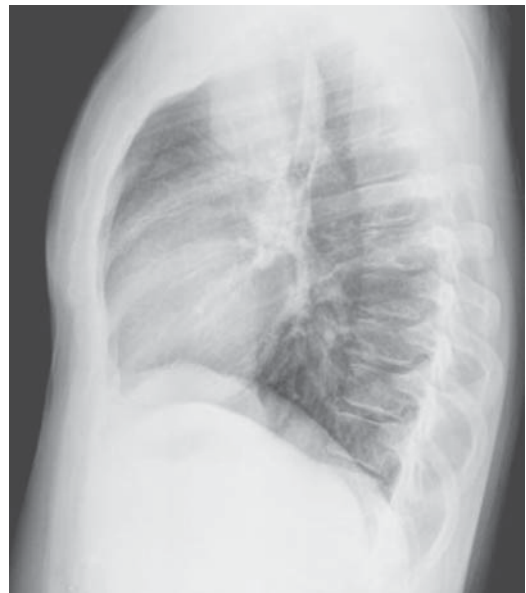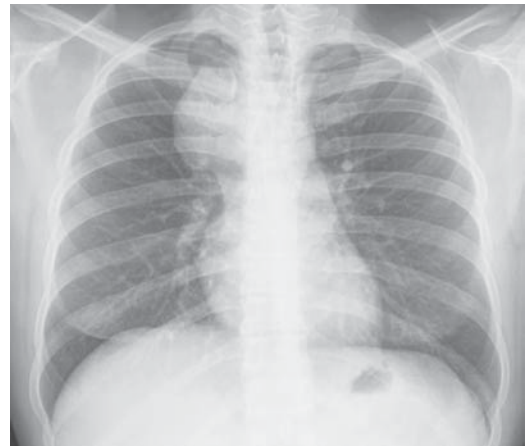Lymphangiomas are lymphatic malformations rather than true neoplasms and are thought to result from failure of the lymphatic system to communicate with the venous system. About 90% of all the cases are diagnosed by the age of two years old. Mediastinal lymphangioma is a rare vascular neoplasm, representing about 0.7 to 4.5% of all mediastinal tumors.<sup>1,2,3</sup> Firstly described in the literature in 1951,<sup>4,5</sup> several case reports and case series have been published, but with a reduced number of patients.<sup>6,7,8</sup>

The rare cases diagnosed in adulthood are, usually, asymptomatic and incidentally detected. The best treatment consists of complete surgical resection.

The authors report a case and make a brief review of clinical presentation, evolution and treatment of this type of tumor.

### Case report

A 33-years-old caucasian man was referred to Pulmonology in April 2005 to clarify a radiological abnormality which was present in a routine chest radiography. The patient did not have any relevant pathological history, although he was a current smoker. At the time of presentation he was asymptomatic. Chest radiograph showed a mediastinal opacity in the anterior mediastinum (Fig. 1 and 2). He underwent a thoracic CT scan that identified a paratracheal and pre-tracheal mediastinal mass, from the cranial plane of supra-aortic vessels to sub-carinal region, well-defined, about 67 mm of longitudinal diameter with hydric content attenuation values (Fig. 3). Fiberoptic bronchoscopy was normal. Transtracheal fine needle aspiration was made, with suction of hydric, clear and yellowish content. Cytological



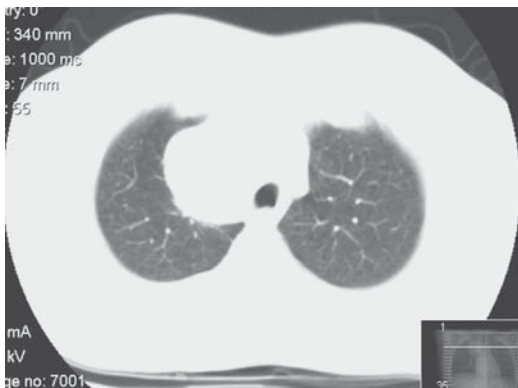**Figs. 1 and 2** – Chest radiograph showing a right-sided opacity in the anterior mediastinum

exam of his was inconclusive, revealing only mature B and T lymphocytes.

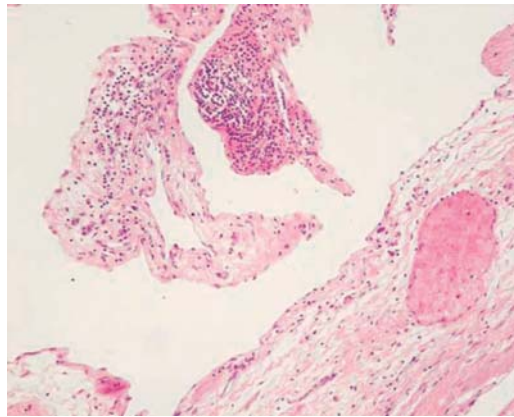
Lung function evaluation was normal. The patient was scheduled for a diagnostic thoracotomy. He underwent complete resection of a cystic mass, which was located between the azygos vein, the superior cava vein and the thorax apex. Macroscopic anatomo-patho-

## LINFANGIOMA CÍSTICO DO MEDIASTINO

Sandra Saleiro, Adriana Magalhães, Conceição Souto Moura, Venceslau Hespanhol



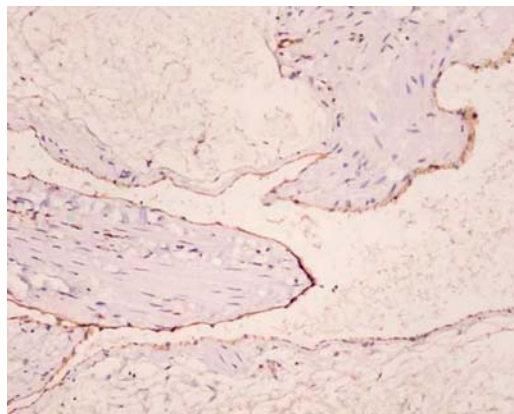
**Fig. 3** – Thoracic computed tomography scan showing a paratracheal and pre-tracheal mediastinal mass, well-defined and with hydric content attenuation values



**Fig. 4** – Large lymphatic channels in a loose connective tissue and collections of lymphocytes in the stroma

logical exam revealed a nodular formation, of 123 g, with 9.5 x 6.5 x 4 cm, and a hump external surface. When it was cut, a multicavity cystic structure with a reddish-yellow fluid content was noted. It should be stressed that the bloody appearance of the cyst's fluid, as well as the presence of numerous lymphocytes, has already been described in literature.<sup>9</sup> Histological exam showed a multiloculated lesion, consisting of large lymphatic channels growing in loose connective tissue, with smooth muscle fibers sometimes disorganised. A follicular organised lymphoid tissue was present in the stroma (Fig 4). Immunohistochemical exam of the cells covering the cysts revealed immunoreactivity to CD 31 and CD 34 (Fig. 5).

There were no complications in the postoperative period. Control chest radiograph performed 45 days after the surgery showed pulmonary expansibility and 6 months later the thoracic CT scan revealed complete normality. Seven months after surgery the patient remains asymptomatic, with no functional limitation.



**Fig. 5** – Immunohistochemical exam revealed immunoreactivity to CD 31 in the cells covering the cyst.

### Discussion

Lymphangioma is usually detected in childhood and occurs mainly in the neck and head region (75% of the cases) and in the axillary region (20%).<sup>10</sup> Cases diagnosed in adulthood are rare and are usually located in the intrathoracic region. Riquet *et al*<sup>6</sup> carried out a retrospective analysis of 37 patients and concluded that in children, teenagers and young adults, lymphangiomas are

located in the neck or anterior mediastinum and have a vascular malformation component and so it should be considered congenital. On the other hand, in older adults these tumors are found predominantly in the posterior or medium mediastinum and are constituted of purely liquid cysts, which suggest an acquired origin.

Turning to pathological characteristics, lymphangioma can be classified in three types: cystic, capillary and cavernous, with the first the most frequent. About 1% of cystic lymphangiomas are located in the mediastinum.<sup>3,11</sup> Cystic lymphangiomas are benign tumors that are usually presented as mediastinal masses of slow growth, showing evidence of progression in terms of tumoral size or invasion of adjacent vital structures. Sometimes this invasion limits the surgical removal of the tumor or makes it difficult.

Most of the patients are asymptomatic, being incidentally diagnosed in adulthood through a routine chest radiograph. Symptoms such as hoarseness, dyspnea, respiratory failure, superior vena cava syndrome or dysphagia occur when the tumor grows and compresses or invades adjacent structures.<sup>8,12,13,14</sup> Chylothorax and chylopericardium are also possible complications which may occur.<sup>15</sup>

In terms of imagiological investigation of this type of tumor, thoracic CT scan seems to be necessary for a better characterisation of the lesion, in terms of size, density and location, although it does not establish its precise nature and so does not allow for a definitive diagnosis. On the other hand, thoracic MRI can be useful in the diagnosis since it can show a multiloculated appearance and a continuous extension of the lesion which suggests the diagnosis of lymphangioma.<sup>8</sup> However, surgery with histological examination of the lesion remains the gold standard for a definitive diagnosis.<sup>8</sup>

The best treatment consists of complete surgical resection of the tumor. Nevertheless, sometimes surgical excision is technically difficult because of the tumor's size or extension, or if it infiltrates mediastinal plans or involves the great vessels. Sclerosis with chemical agents is an alternative treatment and should be considered when surgery is not possible.<sup>16,17</sup>

Okubo *et al* describe a case of cystic lymphangioma located in the right superior mediastinum, in which intralesional administration of OK-432 was made, with an excellent result.<sup>16</sup> In a review of 22 cases of lymphangioma diagnosed in children,<sup>18</sup> sclerosis with intralesional bleomycin was made in three cases, with subsequent complete disappearance of the lesions. However, the author states that experience with this kind of treatment is limited, being surgery considered the treatment of first choice. Thus, sclerotherapy can be useful in cases in which surgery carries a high risk of damage to adjacent structures.

In the cases of incomplete resection of the tumor, there could be an insidious progression of the lesion and subsequent recurrence.<sup>7</sup> If all the tumoral mass has been surgically removed, recovery is complete and recurrence after surgery is not expected.<sup>8,12,19</sup>

The case described is a rare condition of a mediastinal cystic lymphangioma, whose definitive diagnosis was only possible after the histological and immunohistochemical examination of the surgical mass. Despite in this case thoracic CT scan indicating a hydric attenuation pattern here, it did not allow differentiation from other pathologies, namely, cystic teratoma, cystic thymoma or thymic cyst. The case reported occurred in a young adult and was located in the anterior mediastinum, as is usual in lymphangiomas considered congenital. However, the cystic structure of the tumor suggests an acquired origin.<sup>6</sup>

## Bibliography

1. Yacoub MH, Lise M. Intrathoracic cystic hygromas. *Respir Med* 1969; 63: 107-11.
2. Shenoy SS, Barua NR, Patel AR, Culver GJ, Jennings EC. Mediastinal lymphangioma. *J Surg Oncol* 1978; 10: 523-8.
3. Bancel B, Patricot LM, Guerin JC, Vitrey D, Baulieux J. Cystic lymphangioma of the mediastinum. 2 personal cases and a review of the literature. *Ann Pathol* 1991; 11 (2): 107-11
4. Weber G, Smorlesi L. Pathology of mediastinal tumors; lymphangioma, teratoma, neurogenous tumors. *Arch De Vecchi Anat Patol* 1951; 16 (1): 159-216
5. Santy P, Jaubert, Beaujeu M. Cystic lymphangiomas of the mediastinum; two cases; diagnosis of low anterior localizations with pleuropericardial cysts. *J Fr Med Chir Thorac* 1951; 5 (3): 278-84
6. Riquet M, Briere J, Le Pimpec-Barthes F, Bely N, Dujon A, Velly JF, Brichon PY, Faillon JM, Mouroux J, Janovicovici R, Dahan M. Cystic lymphangioma of the neck and mediastinum: are there acquired forms? Report of 37 cases. *Rev Mal Respir* 1999; 16 (1): 71-9
7. Marc K, Kabiri H, Caidi M, El Masslout A, El Fassy Fihry MT, Benosman A. Cystic lymphangioma of the mediastinum. Seven cases. *Rev Pneumol Clin* 2002; 58 (4 Pt 1): 214-8
8. Oshikiri T, Morikawa T, Jinushi E, Kawakami Y, Katoh H. Five cases of lymphangioma of the mediastinum in adults. *Ann Thorac Cardiovasc Surg* 2001; 7: 103-5
9. Sasaki H, Oota T, Kataoka D, Chida M, Maeda S. A case of mediastinal cystic lymphangioma with bloody fluid. *Kyobu Geka* 1997; 50 (9): 805-7
10. Handa R, Kale R, Upadhyay KK. Isolated mediastinal lymphangioma herniating through the intercostals space. *Asian J Surg* 2004; 27 (3): 241-2
11. Brocard H, Blanchon F, Vannier R, Milleron B, Martin M, Akoun G, Almosni M. Isolated cystic lymphangioma in the mediastinum. *Poumon Coeur* 1978; 34 (4): 259-63
12. Okubo T, Okayasu T, Osaka Y, Kajitani M, Hasegawa N, Tanabe T. Surgical analysis of mediastinal lymphangioma – analysis of 7 cases. *Nippon Kyobu Geka Gakkai Zasshi* 1992; 40 (4): 583-6
13. Balkaran BN, Maharaj P, Pitt-Miller P. Intrathoracic cystic hygroma in an infant with respiratory failure. *West Indian Med J* 1997; 46: 128-9
14. Agartan C, Olguner M, Akgur FM. A case of mediastinal cystic hygroma whose only symptom was hoarseness. *J Pediatr Surg* 1998; 33: 642-3
15. Pop D, Benizri EI, Venissac N, Leo F, Padovani B, Mouroux J. Mediastinal cystic lymphangioma: is resection always necessary? *Thorac Cardiovasc Surg* 2005; 53 (4): 243-4
16. Okubo T, Shimada T, Narita Y, Okushiba T, Douke M, Takahashi T, Okushiba S, Motohara T, Katou H. A successful case report on intralesional OK-432 therapy for cystic mediastinal lymphangiomas. *Kyobu Geka* 1998; 51 (12): 1017-21
17. Rakotosamimanana J, Raharisolo CR, Ratovoson H, Ahmad A, Razafindramboa H. Cystic cervical and mediastinal lymphangioma: a case report and review of the literature. *Arch Inst Pasteur Madagascar* 2000; 66 (1-2): 61-4
18. Al-Salem AH. Lymphangiomas in infancy and childhood. *Saudi Med J* 2004; 25 (4): 466-9
19. Minami H, Kubota F, Kawabe H, Kawabuchi T, Kajiwara K, Jibiki M, Nanashima A, Ifuku M. A case report of mediastinal cystic lymphangioma. *Kyobu Geka* 1990; 43 (6): 479-82