

---

**Instantâneo Endoscópico / Endoscopic Spot**

---

**SUCCESSFUL MANAGEMENT OF A BLEEDING DUODENAL VARIX  
BY SCLEROTHERAPY WITH N-BUTYL-2-CYANOACRYLATE**

A. MARTINS, R. ORNELAS, A. VALENTE, R. PALMA, M. RAIMUNDO, A. MARQUES, P. ALEXANDRINO,  
M. CARNEIRO DE MOURA

*GE - J Port Gastroenterol 2006, 13: 293-294*

Duodenal varices are a rare complication of portal hypertension and experience in the control of haemorrhage is limited. Endoscopic approach, using sclerotherapy with N-butyl-2-cyanoacrylate (1,2) or band ligation (3,4), appears to be a safe and efficient first-choice therapy. Other strategies, such as TIPS (5), are mainly reserved when there is failure to control bleeding.

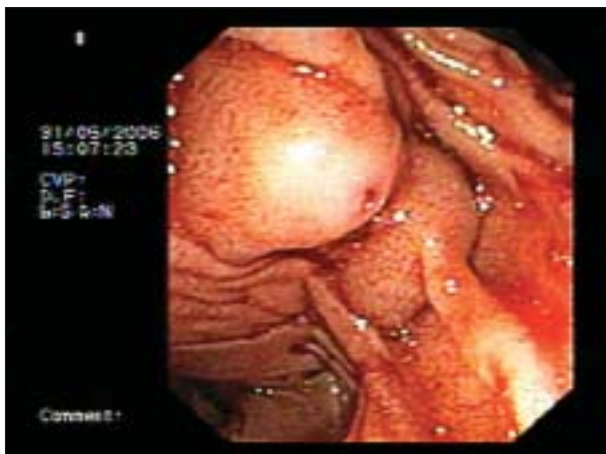
We report the case of a 62-year-old man, with previously diagnosed alcoholic cirrhosis, presenting, for the first time, with melena without hematemesis. An upper gastrointestinal endoscopy showed large esophageal varices, with red spots, without active bleeding, which were submitted to endoscopic band ligation. The patient persisted with melena, needing frequent red blood transfusions to maintain haemodynamic stability. A colonoscopy was undertaken showing diverticula of the left and right colon, without stigmata of recent bleeding. An enhanced contrast CT scan and also a capsule enteroscopy were done and no significant lesions were found. One week after admission, the patient had, for the first time, hematemesis. An upper endoscopy was repeated, revealing recent blood in the duodenum and, in its third

portion, a nodular varix with a central depression, without active bleeding (Figure 1). Using a duodenoscope, it was successfully obliterated with injection of N-butyl-2-cyanoacrylate (diluted with lipiodol 1:1), with a total of 3cc of the mixture (Figure 2). The radioscopic control showed no evidence of pulmonary embolisation. He has now a 6-month period of follow-up free from recurrence of bleeding.

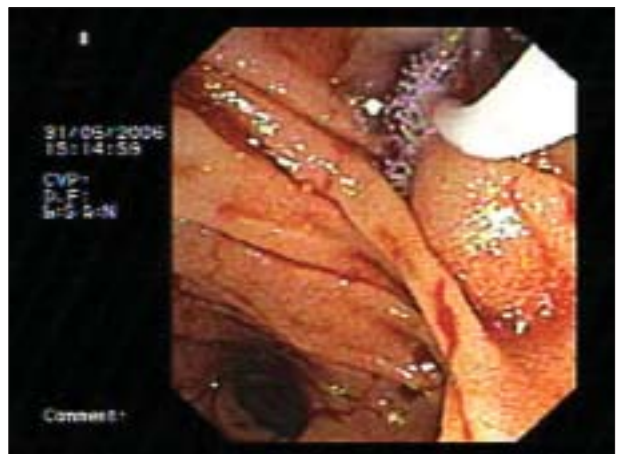
This paper supports that endoscopic injection sclerotherapy with N-butyl-2-cyanoacrylate is effective in achieving immediate cessation of bleeding in duodenal varices and that long-term hemostasis can be expected.

*Correspondência:*

Alexandra Machado Martins  
Serviço de Gastroenterologia, Hospital de Santa Maria  
Av. Prof Egas Moniz  
1649-035 Lisboa, Portugal  
Tel.: 00351 217985187  
Fax: 00351 217985142  
*e-mail:* alexandramartins@hotmail.com



**Figura 1 - Duodenal varix with a central depression, without active bleeding.**



**Figura 2 - Obliteration of the varix with injection of N-butyl-2-cyanoacrylate.**

**BIBLIOGRAFIA**

1. Paupard F, Blain A, Abitbol V et al. Treatment of a hemorrhagic duodenal varice by endoscopic sclerotherapy. *Gastroenterol Clin Biol* 1995;19:1051-4.
2. Sato H, Fujishiro H, Rumi MA et al. Successful endoscopic injection sclerotherapy for duodenal varices. *J Gastroenterol* 2002;37:143-4.
3. Omata F, Itoh T, Shibayama Y et al. Duodenal variceal bleeding treated with a combination of endoscopic ligation and sclerotherapy. *Endoscopy* 1998;30:S62-3.
4. Bosch A, Marsano L, Varilek GW. Successful obliteration of duodenal varices after endoscopic ligation. *Dig Dis Sci* 2003; 48:1809-12.
5. Vangeli M, Patch D, Terreni N et al. Bleeding ectopic varices-treatment with transjugular intrahepatic porto-systemic shunt (TIPS) and embolisation. *J Hepatol* 2004;41:560-6.

---

---

**Errata**

---

No artigo “Liver Disease Due To *Schistosoma Guineensis* - A Review,” da autoria de A. Murinello, N. Germano, P. Mendonça, C. Campos e A. Grácio, publicado no GE de Março/Abril 2006 (Ano XIII - Vol. 13 - Nº 2), na legenda da Figura 1 onde se lê “adapted from ref. 46” deverá ler-se “adapted from ref. 48”.

No artigo “Implantação Metastática em Estoma de Gastrostomia Endoscópica Percutânea”, da autoria de S. Barrias, P. Lago, C. Caetano, C. Nogueira, J. Areias (Ano XIII - Vol. 13 - Nº 6), no Quadro 1, na segunda coluna horizontal do ano 1997, onde se lê “supragótico” deverá ler-se “supraglótico”.