

TRATAMENTO DE ROTURA DE ANEURISMA DA AORTA ABDOMINAL APÓS EVAS COM EXPLANTAÇÃO DO DISPOSITIVO

EVAS DEVICE EXPLANTATION IN A SECONDARY RUPTURE OF AN ABDOMINAL AORTIC ANEURYSM

Alice Lopes*^{1,2}, Tony Soares^{1,2}, Pedro Amorjm^{1,2,3}, Gonçalo Sobrinho^{1,2,3}, Luís Mendes Pedro^{1,2,3}

1. Vascular Surgery Department- Heart and Vessels Division, Hospital de Santa Maria (CHULN), Lisbon, Portugal.

2. Lisbon School of Medicine, University of Lisbon, Portugal

3. Lisbon Academic Medical Center, Lisbon, Portugal

Recebido a 07 de setembro de 2019

Aceite a 30 de abril de 2020

Palavras-chave

EVAS; Aneurisma aorta; Rotura; Endovascular

Keywords

EVAS; Abdominal aortic aneurysm; Aneurysm rupture; Endovascular aneurysm sealing; Endovascular aneurysm repair

Endovascular aneurysm sealing (EVAS) was a relatively new concept that aimed to reduce the incidence of complications after endovascular aneurysm exclusion. However, EVAS device was recently recalled from market due to high risk of graft failure beyond two years after implantation^(1,2). The aim of this paper is to report a case of a post-EVAS ruptured abdominal aortic aneurysm.

A 72-year-old man underwent EVAS and a bilateral sandwich technique of the iliac bifurcation for an aorto-bi-iliac aneurysm in 2015 in another institution. Follow-up CTA at three years showed a type Ib endoleak in the left iliac bifurcation and the patient was kept under clinical and imagiological surveillance (protocol unknown, again at another institution). Four years after the initial procedure the patient was admitted in the emergency department of our hospital after syncope and with abdominal pain. The CT-angiography (CTA) revealed a post-EVAS rupture in the distal aorta suggesting an endobag rupture (Fig 1). The patient underwent open surgical repair with explantation of the EVAS device (Fig 2 and 3) and an aorto-bifemoral interposition with a Dacron graft. The procedure was uneventful and the post-operative CTA showed a patent aorto-bifemoral graft without evidence of any complications (Fig. 4). One week later the patient was discharged home in good clinical condition.

Post-operative surveillance is important in any aortic aneurysm endovascular procedure. However, since the last EVAS studies, all patients submitted to this technology must be

under strict surveillance to identify complications like endobag rupture that can lead, as in the reported case, to aneurysm rupture which in turn can lead to stent graft explantation in an emergency setting⁽¹⁻⁴⁾.

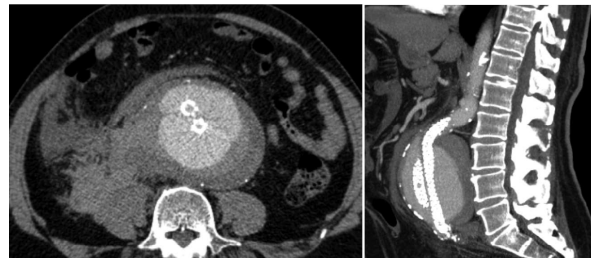


Figure 1

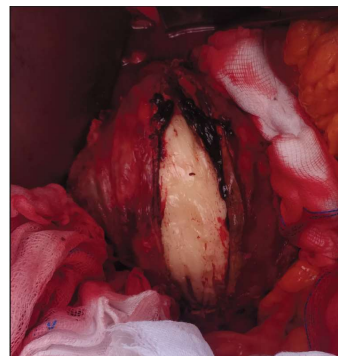


Figure 2

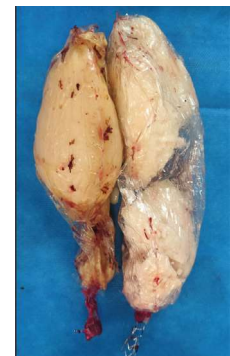

Figure 3

*Autor para correspondência.

Correio eletrónico: alicerclopes@gmail.com (A. Lopes).

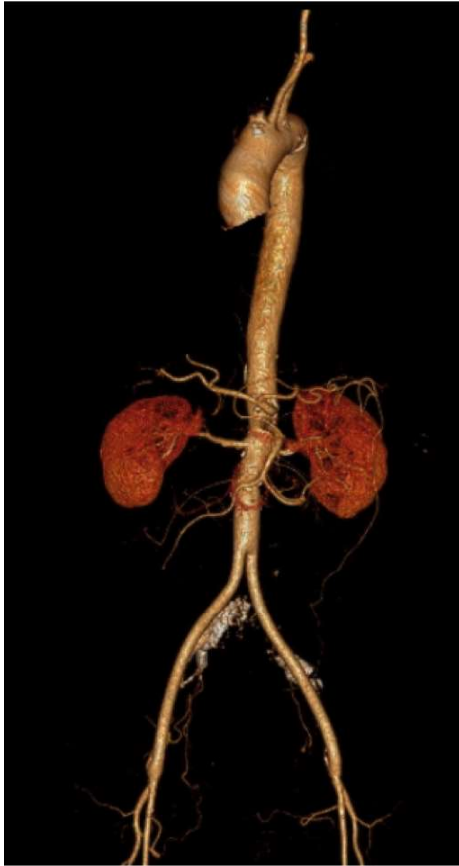

Figure 4

REFERENCES

1. Stenson KM, Bruin JL, Loftus IM, Holt PJE. Migration and sac expansion as modes of midterm therapeutic failure after endovascular aneurysm sealing: 295 cases at a single center. *J Vasc Surg* 2019; 71(2):457-469.
2. Endologix provides update on previously announced voluntary Nellix System recall. Available at: <https://endologix.com/wp-content/uploads/2019/01/2019.01.22-Press-Release-Nellix-CE-Mark-FINAL.pdf>. Accessed January 2019.
3. Hilliard NJ, Hayes P, Winterbottom AP. Appearance of the Nellix endoprosthesis on postoperative imaging: implications for patient and device surveillance. *Semin Vasc Surg* 2016;29:126-34.
4. Jones JE, Atkins MD, Brewster DC, Chung TK, Kwolek CJ, LaMuraglia GM, et al. Persistent type 2 endoleak after endovascular repair of abdominal aortic aneurysm is associated with adverse late outcomes. *J Vasc Surg* 2007;46:1-8.

