

DISSEÇÃO ISOLADA DA ARTÉRIA ILÍACA EXTERNA

ISOLATED EXTERNAL ILIAC ARTERY DISSECTION

Mário Moreira*¹, Mafalda Correia¹, Joana Moreira¹, Luís Antunes¹, Manuel Fonseca¹

1. Angiology and Vascular Surgery Department, Centro Hospitalar e Universitário de Coimbra

Recebido a 27 de fevereiro de 2020

Aceite a 30 de abril de 2020

RESUMO

A disseção espontânea e isolada da artéria ilíaca externa é rara. A evolução clínica desta patologia é variável. Os autores apresentam o caso de um militar, 54 anos, com espondilite anquilosante que apresenta claudicação do membro inferior secundária a disseção isolada da artéria ilíaca externa. A disseção foi tratada através de angioplastia com colocação de stent.

Palavras-chave

Disseção isolada; Artéria ilíaca externa; Endovascular

ABSTRACT

Spontaneous and isolated dissection of external iliac artery is very rare. The natural course of this condition is not well established. The authors report a case of a 54 year old male, military, with ankylosing spondylitis presenting with limb claudication secondary to isolated dissection of external iliac artery. Dissection was successfully managed by percutaneous stent placement.

Keywords

Isolated dissection; External iliac artery; Endovascular

INTRODUCTION

Spontaneous dissection of the peripheral arteries without involvement of the aorta is rare; when affecting iliac arteries, common iliac artery is usually involved. Isolated dissection of external iliac artery (EIA) is a rare pathologic process, more often caused by iatrogenic trauma during percutaneous arterial access or blunt injury; only a few cases of spontaneous dissection of EIA are reported in the literature, mostly in patients with connective tissue disorders and in highly trained athletes or some occupational activities⁽¹⁾. Considering the rarity of the condition, natural course is not well established; patients can remain asymptomatic, present with acute or chronic limb ischemia, or develop aneurysmal dilatation of the involved segment with subsequent risk of rupture. Local pain is sometimes referred. Although spontaneous healing with conservative treatment was previously reported⁽²⁾, surgical or endovascular treatment has been used in most cases with good results.

CASE REPORT

A 54-year-old white male, military (on administrative functions in recent years), presented with calf and thigh claudication at approximately 100m on right lower limb for months, interfering with activities of daily living. Past medical history included arterial hypertension, ankylosing spondylitis and right thyroid lobectomy for benign node; there was no history of trauma. Physical examination with all pulses symmetrically palpable in both lower limbs. Normal ankle-brachial index (ABI) at rest; however, a 30mmHg drop in right lower limb pressure at the ankle was noted after the patient was asked to walk until symptoms arise. Computed tomography showed isolated right EIA dissection with an extension of 23mm and stenosis of the true lumen (Fig. 1).

*Autor para correspondência.

Correio eletrónico: mariodpmoreira@gmail.com (M. Moreira),

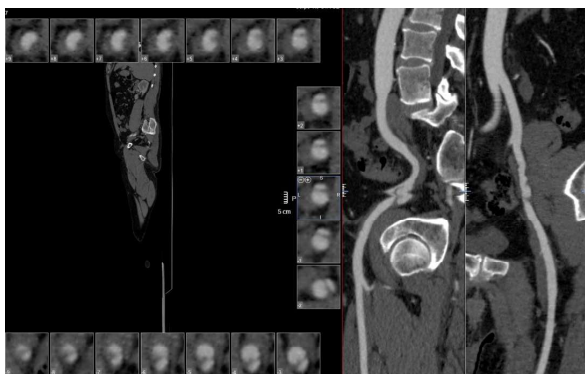


Figure 1 CT showing isolated dissection of external iliac artery.

Evaluation of lumbar spine displayed slight degenerative changes. After retrograde right femoral puncture (6F), angioplasty with 9x40mm Complete® self-expandable stent was performed (Fig. 2 and 3).

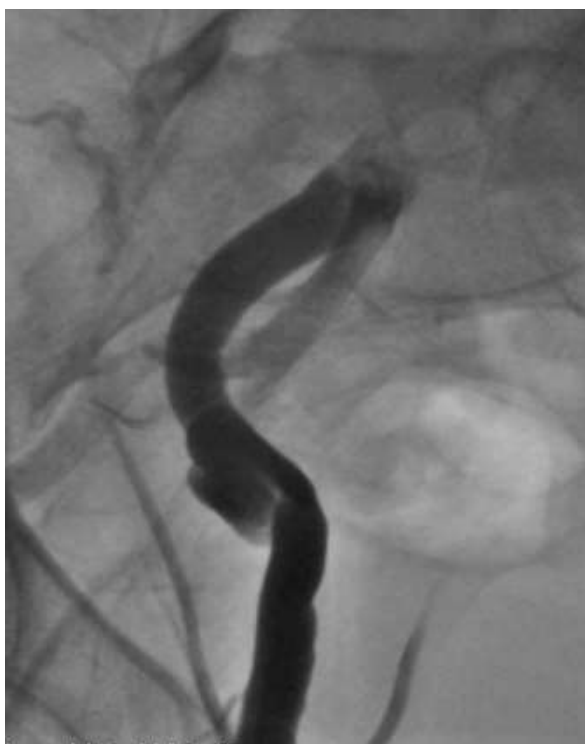

Figure 2 Initial angiography.

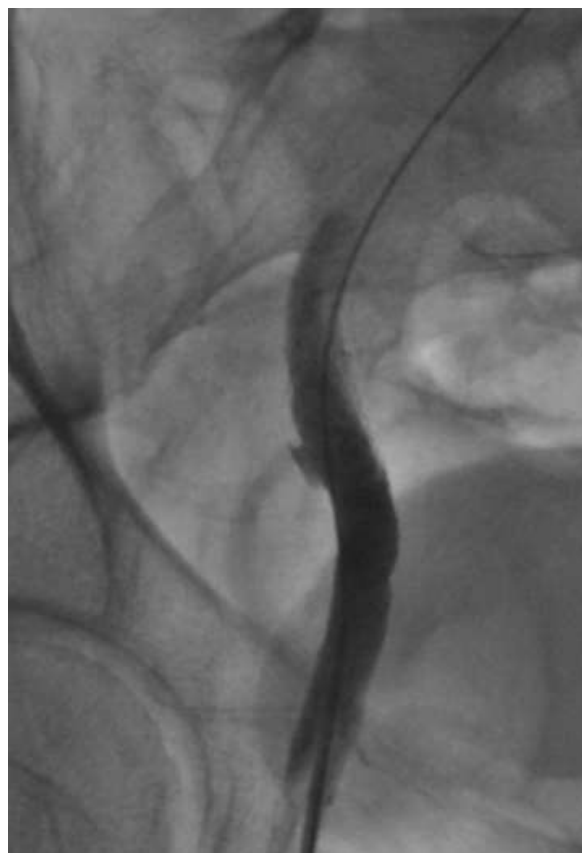


Figure 3 Angiography after stent deployment.

A 9mm balloon catheter was used to appose the stent. The patient was discharged on the next day with antiplatelet therapy (acetylsalicylic acid, 100 mg/daily). Follow-up was scheduled on the first, sixth and twelfth post-operative month and yearly thereafter with clinical evaluation, ABI measurement and duplex ultrasound. At 24 months follow-up, the patient remain free of symptoms.

DISCUSSION

Best treatment for this condition is not established. Conservative treatment is sometimes enough to heal the dissection⁽²⁾ but patients on this report were either asymptomatic or complaining of local pain, with no symptoms of limb ischemia. Endovascular treatment of isolated EIA dissection is a viable treatment option. The goal is to exclude the false lumen from bloodstream by closing the tear. Self-expandable stent placement has high radial force to produce compression and local thrombosis of the false lumen. Ensuing ballooning is debatable^(3,4) because spot stenting is usually sufficient to exclude the dissected zone from bloodstream and additional angioplasty can cause dissection at stent edge.



Our decision was to perform balloon angioplasty to fully expand the deployed stent in order to appose the stent to all layers of artery wall which was done safely by confining dilatation to the inner area of the stent. Covered stents can be useful in some cases particularly when there multiple entry and re-entry sites⁽³⁾, which was not evident in our patient. Anatomical features of EIA should be taken in account when stenting is planned; risk of stent kinking, fracture or dislocation should be considered. This is particularly relevant in highly trained athletes who express desire to return to practice⁽¹⁾. In more complex cases intravascular ultrasound can be a useful adjunct to confirm true lumen stenting⁽⁵⁾. This case highlights the value of ankle pressure/ABI comparison at rest and after exercise. Pressure reduction across a stenosis is dependent on the flow rate through it. It is a useful and practical method to evaluate the functional effect of arterial insufficiency and distinguish arterial claudication from other causes. The dissection's etiology is quite intriguing. The patient has no history of trauma and despite being a military, he perform only office-based tasks. Ankylosing spondylitis and other spondyloarthropathies are associated with increased cardiovascular risk compared to general population⁽⁶⁾. Although we did not find reports about isolated EIA dissection and ankylosing spondylitis, this can be explained by the rarity of isolated EIA dissection as there are reports on dissection affecting other arteries. However, the questions about dissection's etiology should warrant lifelong surveillance.

CONCLUSION

Isolated external iliac artery dissection is extremely rare. In selected cases, stenting appears to be a safe and effective treatment.

REFERENCES

1. Yamanaka Y, Yoshida T, Nagaoka E. Bilateral external iliac artery dissection in a middle-aged male athlete. *Ann Vasc Dis*. 2017; 10(4):446-448. DOI:10.3400/avd.cr.17-00072
2. Liang Z, Guo W, Du C, Xie Y. Effectiveness of the conservative therapy for spontaneous isolated iliac artery dissection: Preliminary results. *Vascular* 2017; 25(6):649-656. DOI: 10.1177/1708538117710845
3. Yoshida RA, Kolvenbach R, Vieira PRB, Moura R, Jaldin RG, Yoshida WB. Endovascular treatment of spontaneous isolated common and external iliac artery dissections with preservation of pelvic blood flow. *Ann Vasc Surg* 2015; 29(1):126.e9-14. DOI: 10.1016/j.avsg.2014.08.013
4. Spinella G, Pane B, Perfumo MC, Palombo D. Spontaneous iliac artery dissection treated with a combination of covered and self-expandable stents to preserve hypogastric patency. *J Vasc Surg Cases* 2016; 2:14-7. DOI: 10.1016/j.jvsc.2016.02.003
5. Muradi A, Yamaguchi M, Idoguchi K, Nomura Y, Okada T, Sakamoto N, et al. Hybrid management for spontaneous isolated dissection of the iliofemoral artery. *Ann Vasc Surg* 2014; 28(2):490.e13-6. DOI: 10.1016/j.avsg.2013.04.018
6. Agca R, Heslinga SC, Rollefstad S, Heslinga M, McInnes IB, Peters MJL, et al. EULAR recommendations for cardiovascular disease risk management in patients with rheumatoid arthritis and other forms of inflammatory joint disorders: 2015/2016 update. *Ann Rheum Dis* 2017; 76(1):17-28. DOI: 10.1136/annrheumdis-2016-209775